

## A multi-institutional experience in adventitial cystic disease



Raghu L. Motaganahalli, MD,<sup>a</sup> Matthew R. Smeds, MD,<sup>b</sup> Michael P. Harlander-Locke, MPH,<sup>c</sup> Peter F. Lawrence, MD,<sup>c</sup> Naoki Fujimura, MD, PhD,<sup>d</sup> Randall R. DeMartino, MD, MS,<sup>e</sup> Giovanni De Caridi, MD, PhD,<sup>f</sup> Alberto Munoz, MD,<sup>g</sup> Sherene Shalhub, MD, MPH,<sup>h</sup> Susanna H. Shin, MD,<sup>h</sup> Kwame S. Amankwah, MD, MSc,<sup>i</sup> Hugh A. Gelabert, MD,<sup>c</sup> David A. Rigberg, MD,<sup>c</sup> Jeffrey J. Siracuse, MD,<sup>j</sup> Alik Farber, MD,<sup>j</sup> E. Sebastian Debus, MD, PhD,<sup>k</sup> Christian Behrendt, MD,<sup>k</sup> Jin H. Joh, MD, PhD,<sup>l</sup> Naveed U. Saqib, MD,<sup>m</sup> Kristofer M. Charlton-Ouw, MD,<sup>m</sup> and Catherine M. Wittgen, MD,<sup>n</sup> on behalf of the Vascular Low-Frequency Disease Consortium, Indianapolis, Ind; Little Rock, Ark; Los Angeles, Calif; Tokyo, Japan; Rochester, Minn; Messina, Italy; Bogota, Colombia; Seattle, Wash; Syracuse, NY; Boston, Mass; Hamburg, Germany; Seoul, Korea; Houston, Tex; and St. Louis, Mo

### ABSTRACT

**Background:** Adventitial cystic disease (ACD) is an unusual arteriopathy; case reports and small series constitute the available literature regarding treatment. We sought to examine the presentation, contemporary management, and long-term outcomes using a multi-institutional database.

**Methods:** Using a standardized database, 14 institutions retrospectively collected demographics, comorbidities, presentation/symptoms, imaging, treatment, and follow-up data on consecutive patients treated for ACD during a 10-year period, using Society for Vascular Surgery reporting standards for limb ischemia. Univariate and multivariate analyses were performed comparing treatment methods and factors associated with recurrent intervention. Life-table analysis was performed to estimate the freedom from reintervention in comparing the various treatment modalities.

**Results:** Forty-seven patients (32 men, 15 women; mean age, 43 years) were identified with ACD involving the popliteal artery (n = 41), radial artery (n = 3), superficial/common femoral artery (n = 2), and common femoral vein (n = 1). Lower extremity claudication was seen in 93% of ACD of the leg arteries, whereas patients with upper extremity ACD had hand or arm pain. Preoperative diagnosis was made in 88% of patients, primarily using cross-sectional imaging of the lower extremity; mean lower extremity ankle-brachial index was 0.71 in the affected limb. Forty-one patients with lower extremity ACD underwent operative repair (resection with interposition graft, 21 patients; cyst resection, 13 patients; cyst resection with bypass graft, 5 patients; cyst resection with patch, 2 patients). Two patients with upper extremity ACD underwent cyst drainage without resection or arterial reconstruction. Complications, including graft infection, thrombosis, hematoma, and wound dehiscence, occurred in 12% of patients. Mean lower extremity ankle-brachial index at 3 months postoperatively improved to 1.07 ( $P < .001$ ), with an overall mean follow-up of 20 months (range, 0.33-9 years). Eight patients (18%) with lower extremity arterial ACD required reintervention (redo cyst resection, one; thrombectomy, three; redo bypass, one; balloon angioplasty, three) after a mean of 70 days with symptom relief in 88%. Lower extremity patients who underwent cyst resection and interposition or bypass graft were less likely to require reintervention ( $P = .04$ ). One patient with lower extremity ACD required an above-knee amputation for extensive tissue loss.

**Conclusions:** This multi-institutional, contemporary experience of ACD examines the treatment and outcomes of ACD. The majority of patients can be identified preoperatively; surgical repair, consisting of cyst excision with arterial reconstruction or bypass alone, provides the best long-term symptomatic relief and reduced need for intervention to maintain patency. (J Vasc Surg 2017;65:157-61.)

From the Division of Vascular Surgery, Indiana University School of Medicine, Indianapolis<sup>a</sup>; the Division of Vascular and Endovascular Surgery, University of Arkansas for Medical Sciences, Little Rock<sup>b</sup>; the Division of Vascular Surgery, University of California Los Angeles, Los Angeles<sup>c</sup>; the Division of Vascular Surgery, Keio University School of Medicine, Shinjuku, Tokyo<sup>d</sup>; the Division of Vascular and Endovascular Surgery, Mayo Clinic, Rochester<sup>e</sup>; the Department of Cardiovascular and Thoracic Sciences, University of Messina, Messina<sup>f</sup>; the National University of Colombia, Bogota<sup>g</sup>; the Division of Vascular Surgery, University of Washington, Seattle<sup>h</sup>; the Division of Vascular Surgery, Upstate Medical University, Syracuse<sup>i</sup>; the Division of Vascular and Endovascular Surgery, Boston University School of Medicine, Boston<sup>j</sup>; the Department of Vascular Medicine, University Heart Center Hamburg, Hamburg<sup>k</sup>; the Division of Vascular and Endovascular Surgery, Kyung Hee University School of Medicine, Gangdong-gu, Seoul<sup>l</sup>; the Department of Cardiothoracic and Vascular Surgery, University of Texas Health Science

Center at Houston, Houston<sup>m</sup>; and the Division of Vascular Surgery, Saint Louis University School of Medicine, St. Louis.<sup>n</sup>

Author conflict of interest: none.

Presented at the 2016 Spring Meeting of the Vascular and Endovascular Surgery Society, National Harbor, Md, June 8-11, 2016.

Correspondence: Peter F. Lawrence, MD, 200 UCLA Medical Plaza, Ste 526, Los Angeles, CA 90095 (e-mail: [pflawrence@mednet.ucla.edu](mailto:pflawrence@mednet.ucla.edu)).

The editors and reviewers of this article have no relevant financial relationships to disclose per the JVS policy that requires reviewers to decline review of any manuscript for which they may have a conflict of interest.

0741-5214

Copyright © 2016 The Authors. Published by Elsevier Inc. on behalf of the Society for Vascular Surgery. This is an open access article under the CC BY-NC-ND license (<http://creativecommons.org/licenses/by-nc-nd/4.0/>).

<http://dx.doi.org/10.1016/j.jvs.2016.08.079>

Adventitial cystic disease (ACD) is a rare, nonatherosclerotic arteriopathy, predominantly affecting the arteries of the lower extremity. Since its original description in 1947,<sup>1</sup> our understanding of the disease is based predominantly on individual case reports and collective reviews of case reports. The prevalence of this arteriopathy remains unknown, with an estimated 500 cases reported in the literature.<sup>2</sup> This disease primarily affects the popliteal arteries, with accumulation of mucinous or gelatinous material in the adventitia of the vessel wall. The initial diagnosis is usually made during assessment of claudication in young patients, but currently there is no uniform approach to the diagnosis or management of these patients. Treatment options include cyst drainage or excision alone, interposition graft or bypass without cyst resection, and interposition graft or bypass with cyst resection.

The aim of this multicenter study was to identify current practice patterns in the diagnosis of ACD patients and to determine differences in outcomes after the various treatment options.

## METHODS

Patients included in this study were identified at multiple institutions that collaborated on this project and were treated for ACD between 2005 and 2015. Patients were identified by pre-existing institutional vascular disease databases, in addition to searching of pathology and radiology hospital records as well as billing databases and operating log books. *International Classification of Diseases, Ninth Revision* codes 443.9 (peripheral arterial disease not otherwise specified) and 447.8 (other specified disorders of arteries and arterioles) were also used for disease identification as there is no specific code for ACD. Diagnosis of ACD was confirmed pathologically. Primary study end points were amputation and need for reintervention.

**Vascular Low-Frequency Disease Consortium (VLFDC) and database management.** The methodology of the VLFDC process has been described previously in detail.<sup>3,4</sup> It was the responsibility of the principal investigator at each institution to obtain Institutional Review Board (IRB) approval; all IRBs waived patient consent because of the minimal risk and retrospective nature of the study. After IRB approval, patients were identified, standardized data were collected using Society for Vascular Surgery reporting standards for lower extremity ischemia,<sup>5</sup> and then the data were deidentified and transmitted to the VLFDC at the University of California Los Angeles, where data were stored in a secure server. The principal investigators from each institution were responsible for the validity and completeness of submitted data from their institutions. All VLFDC investigators reviewed the collective data before abstract submission, meeting presentation, and manuscript submission.

**Statistics.** Data were collected and maintained in an Excel v16.0 database (Microsoft Corp, Redmond, Wash). Statistical analysis was performed with SPSS Statistics v24.0 software (IBM Corp, Armonk, NY) and Prism 7.0 software (Graph Pad Software, La Jolla, Calif). Continuous variables are presented as mean  $\pm$  standard deviation (SD) unless otherwise noted. Differences between subgroups were analyzed using paired Student *t*-test, analysis of variance, Kruskal-Wallis test, and Mann-Whitney *U* test. Unless numeric values are given, percentages are not inclusive. Differences between subgroups of noncontiguous variables were analyzed using  $\chi^2$  test and Fisher exact test. Multivariable analysis was performed using binary and multinomial logistic regression models. Time-dependent variables were analyzed using Kaplan-Meier life tables. A *P* value  $<$  .05 was considered significant. Only the patient's primary treatment was included in the analysis; any subsequent procedures are stated for completeness but not considered for analysis. Unless stated otherwise, analysis of treatment and outcomes includes only patients with lower extremity arterial ACD.

## RESULTS

**Patient demographics and comorbidities.** A total of 47 patients (32 male, 15 female) were treated for ACD at 14 institutions (range, 1-10 cases per institution). The majority of ACD cases (43/47 [92%]) were lower extremity arterial lesions, with 41 (95%) located in the popliteal artery and 2 (5%) within the femoral artery. The remaining patients had lesions in the radial arteries ( $n = 3$  [6%]) and common femoral vein ( $n = 1$  [2%]; Table I). Patients with lower extremity arterial ACD had a mean age of 43 years (range, 25-68 years), and the majority were male ( $n = 32$  [74%]). Hypertension was the most common comorbidity, occurring in 12 (28%), and the majority of patients (30/43 [70%]) were current smokers or ex-smokers (Table II).

**Symptoms/presentation and diagnosis.** Most patients with lower extremity arterial ACD presented with claudication (93%), although two had ischemic rest pain and one had tissue loss. The mean ankle-brachial index at initial evaluation was 0.7 (range, 0.25-1.2; SD, 0.26) and most patients (38/43 [88%]) were diagnosed with ACD preoperatively. Of these patients, 29 of 38 (76%) had cross-sectional imaging with either computed tomography angiography or magnetic resonance imaging/magnetic resonance angiography; only 9 patients underwent preoperative diagnostic catheter angiography (Table III).

**Treatment.** Surgical treatment was performed in 41 of 43 (95%) lower extremity patients; the remaining two patients underwent percutaneous cyst drainage. All procedures were performed by vascular surgeons. The most common procedure used was cyst resection with interposition graft (49%), followed by cyst resection and cyst

**Table I.** Patients with nonlower extremity arterial adventitial cystic disease (ACD)

Patient	Location of lesion	Patient demographics	Diagnosis	Treatment	Outcome
1	Radial artery	54-year-old woman	MRI	Cyst excision	6-month follow-up with no recurrence, symptoms, or loss of patency
2	Radial artery	46-year-old woman	MRI	Cyst excision	4-month follow-up with no recurrence, symptoms, or loss of patency
3	Radial artery	62-year-old woman	MRI	No treatment	9-month follow-up, still symptomatic
4	Common femoral vein	55-year-old woman	CTA/MRI	Cyst excision	30-day follow-up with no recurrence of symptoms and a patent vein

CTA, Computed tomography angiography; MRI, magnetic resonance imaging.

**Table II.** Comorbidities of patients with lower extremity arterial adventitial cystic disease (ACD; N = 43 patients)

Comorbidity	No. (%)
Current smoker or ex-smoker	30 (70)
Hypertension	12 (28)
Dyslipidemia	4 (10)
Hyperlipidemia	3 (7)
Diabetes mellitus	3 (7)

**Table III.** Imaging modalities used for preoperative diagnosis of lower extremity arterial adventitial cystic disease (ACD; N = 38 patients)

Imaging modality	No. (%)
Duplex ultrasound	30 (79)
MRI/MRA	18 (47)
CTA	16 (42)
Catheter angiography	14 (37)

CTA, Computed tomography angiography; MRA, magnetic resonance angiography; MRI, magnetic resonance imaging.

**Table IV.** Procedures performed on patients with lower extremity arterial adventitial cystic disease (ACD)

Procedure	No. (%)
Cyst drainage without resection	2 (5)
Cyst resection	13 (30)
Cyst resection with patch	2 (5)
Cyst resection with interposition graft	21 (49)
Cyst resection with bypass graft	5 (12)

resection with bypass (Table IV), through a posterior approach to the popliteal artery. Overall, 26 of 43 (61%) patients underwent bypass (with or without cyst resection), and vein was the conduit of choice in 92% of the patients. There was no correlation between patient characteristics or comorbidities and patient management. One patient with end-stage renal disease and numerous other comorbidities underwent primary amputation for

extensive tissue loss after being lost to follow-up for several years. The mean length of hospital stay was 7 days (range, 1-27 days; SD, 6 days), with a mean time to return to work of 21 days (range, 2-90 days; SD, 17 days). Symptomatic relief was universal, and postoperative ankle-brachial index improved to 1.07 (SD, 0.22; compared with preoperative, 0.7;  $P < .01$ ). There were no differences in complications, length of hospital stay, or time to return to work on the basis of treatment, and no perioperative deaths occurred within 30 days of procedure (Table V). Required follow-up procedures to maintain patency included thrombectomy (three), balloon angioplasty (three), redo cyst resection (one), and redo bypass (one). The mean time from initial index procedure to secondary intervention to maintain patency was 70 days.

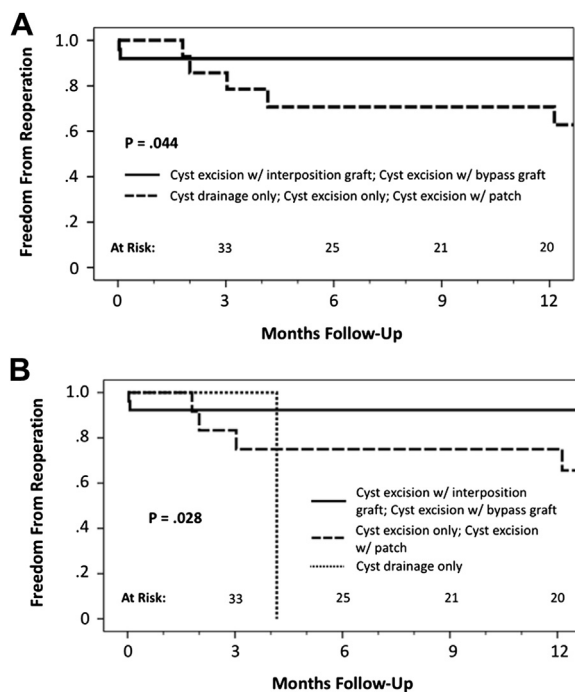
Mean follow-up for all patients was 20 months. Repair with bypass procedure (with or without cyst resection) resulted in longer freedom from reoperation than did cyst excision or drainage alone or with patch of the affected artery (Fig). Only one patient who underwent bypass had loss of patency, which was identified at 6 years and treated with balloon angioplasty. One patient who underwent percutaneous needle aspiration (cyst drainage without reconstruction) required surgical revision with cyst resection and interposition graft 3 weeks after the initial drainage was performed because of recurrence of symptoms and the cystic mass. The cystic lesion recurred in one patient who initially had cyst resection only; treatment was repeated cyst resection.

## DISCUSSION

ACD is a rare disease whose treatment has previously been based on experience documented in case reports. Through use of a multi-institutional data collection process, we were able to identify a large cohort of patients with ACD and to determine current diagnostic and treatment approaches; our series is the largest reported in the literature. Similar to previously published case reports,<sup>2</sup> the popliteal artery was the most common site for involvement. Other arteries reported to be involved include the radial, external iliac,<sup>6</sup> femoral,<sup>7</sup> and axillary arteries<sup>8</sup>; there has also been an occasional case reported in

**Table V.** Postoperative data for patients with lower extremity arterial adventitial cystic disease (ACD)

	Cyst drainage without resection	Cyst resection	Cyst resection with patch	Cyst resection with interposition graft	Cyst drainage with bypass	P value
Length of hospital stay	2	5	7	9	4	.13
Complications	0	2	1	1	1	.40
Time to return to work	14	23	16	18	30	.11
Follow-up procedures	1 (50%)	3 (23%)	1 (50%)	1 (50%)	2 (40%)	.37



**Fig. A.** Freedom from reoperation after primary intervention for patients with lower extremity arterial adventitial cystic disease (ACD) grouped by operation type (cyst excision with interposition graft and cyst excision with bypass graft vs cyst drainage alone, cyst excision only, and cyst excision with patch). Standard error exceeds 10% at time points >5 months. **B.** Freedom from reoperation after primary intervention for patients with lower extremity arterial ACD grouped by operation type (cyst excision with interposition graft and cyst excision with bypass graft vs cyst excision only and cyst excision with patch vs cyst drainage only). Standard error exceeds 10% at time points >4 months.

the venous system. Case reports as well as our own indicate that ACD is an arteriopathy that affects primarily young men, who had a mean age of 43 years.<sup>2,9</sup> As opposed to prior reports, our series revealed a high percentage of patients with a history of smoking; 71% of our patients were either active smokers or ex-smokers, suggesting that the disease entity should be considered in the differential diagnosis of any young patient with claudication, irrespective of smoking status. These cysts have been suggested to form secondary to adventitial degeneration as a result of trauma, to be remnant

mesenchymal rests during development, or to arise from synovial origins,<sup>10</sup> which may imply that smoking is a noncausal association, although the exact pathogenesis of ACD is poorly understood and controversial.

Similar to previous reports,<sup>2,9</sup> most patients in our series presented with claudication (93%), although one patient with extensive tissue loss required an amputation because of a nonsalvageable limb, whereas patients with venous involvement generally had symptoms such as swelling, resulting from local compression. In contrast to earlier reports that identified the angiographic “scimitar” sign as pathognomonic for ACD, the majority of the patients in our series (76%) did not have catheter angiography but rather had their diagnosis made preoperatively by noninvasive duplex ultrasound, whereas cross-sectional imaging with contrast-enhanced computed tomography or magnetic resonance imaging<sup>11</sup> was used for detailed anatomic information before treatment. Cross-sectional imaging studies also provided information about the presence or absence of communication with the joint cavity. Communication with the joint cavity supports the mesenchymal migration theory of ACD etiology that proposes that during development, mesenchymal cells migrate from the joint tendon to the adjacent arterial (or venous) adventitia, resulting in the formation of the cyst by the mucin-secreting cells.

Various treatment options exist for ACD, ranging from ultrasound-guided aspiration to open cyst excision, patch angioplasty, interposition graft, and bypass with or without cyst excision.<sup>2,7,9</sup> In our series, bypass with or without cyst excision provided the most durable option for symptomatic relief as well as resulting in longer freedom from reintervention. One patient had recurrence after initial treatment with local cyst excision. This patient required repeated cyst excision and currently remains free of recurrence.

On the basis of our series, bypass or interposition graft procedures, ideally with cyst excision, provide good durability with freedom from reintervention. Recurrences are common with cyst excision procedures, particularly when a portion of the cyst is left behind.<sup>12</sup> This is thought to be due to persistence of the secretory components of the adventitial cyst. Two of our patients had ultrasound-guided cyst aspiration and one presented with recurrent symptoms 28 days after the initial procedure. He was treated with excision of the cyst and vein interposition

graft and has been symptom free on follow-up. Unlike simple cysts with no septations, the cysts in patients with ACD have complex morphology, and the contents of the cyst are more mucoid and gelatinous,<sup>2,12-14</sup> so difficulties in draining the cyst contents with a single aspiration are not unexpected. Furthermore, the contents of the cyst also contain high concentrations of hyaluronic acid and so are difficult to extract through small-gauge needles. Whereas drainage techniques have been described in the literature,<sup>15,16</sup> multiple reports identify recurrence after cyst drainage alone.<sup>17-19</sup>

The primary limitation of this study is its retrospective nature, so we could not prevent patient selection bias regarding patient management or determine which factors contributed to the decision-making process. In addition, imaging modalities and criteria for diagnosis and treatment were not standardized and varied by institution and surgeon. Given the rarity of ACD, treatment strategies have been guided predominantly by case reports, which lack the power to offer convincing evidence of superiority. The collaboration of centers in our study allows a more robust statistical analysis than has been previously available.

## CONCLUSIONS

This multi-institutional experience in managing ACD supports previous case reports showing that the popliteal artery is the most common site for involvement and that claudication is the most common presenting symptom. Noninvasive imaging modalities are frequently used for diagnosis. Of the currently available treatment options for patients with ACD, cyst resection with interposition or bypass graft is associated with the greatest likelihood of resolution of symptoms and reduced need for reintervention due to cyst recurrence. Cyst drainage alone may result in recurrence and the need for reintervention.

## AUTHOR CONTRIBUTIONS

Conception and design: RM, MS, MHL, PL

Analysis and interpretation: RM, MS, MHL, PL, NF, RD, GDC, AM, SS, SHS, KA, HG, DR, JS, AF, ED, CB, JJ, NS, KCO, CW

Data collection: RM, MS, MHL, PL, NF, RD, GDC, AM, SS, SHS, KA, HG, DR, JS, AF, ED, CB, JJ, NS, KCO, CW

Writing the article: RM, MS, MHL, PL

Critical revision of the article: RM, MS, MHL, PL, NF, RD, GDC, AM, SS, SHS, KA, HG, DR, JS, AF, ED, CB, JJ, NS, KCO, CW

Final approval of the article: RM, MS, MHL, PL, NF, RD, GDC, AM, SS, SHS, KA, HG, DR, JS, AF, ED, CB, JJ, NS, KCO, CW

Statistical analysis: MHL

Obtained funding: Not applicable

Overall responsibility: PL

RM and MS share first authorship.

## REFERENCES

1. Atkins HJ, Key JA. A case of myxomatous tumor arising in the adventitia of the left external iliac artery: case report. *Br J Surg* 1947;34:426-7.
2. Desy NM, Spinner RJ. The etiology and management of cystic adventitial disease. *J Vasc Surg* 2014;60:235-45.
3. Smeds MR, Duncan AA, Harlander-Locke MP, Lawrence PF, Lyden S, Eskandari MK, et al. Treatment and outcomes of aortic endograft infection. *J Vasc Surg* 2016;63:332-40.
4. Klausner JQ, Lawrence PF, Harlander-Locke MP, Coleman DM, Stanley JC, Fujimura N, et al. The contemporary management of renal artery aneurysms. *J Vasc Surg* 2015;61:978-84.
5. Rutherford RB, Baker JD, Ernst C, Johnston KW, Porter JM, Ahn S, et al. Recommended standards for reports dealing with lower extremity ischemia: revised version [erratum in: *J Vasc Surg* 2001;33:805]. *J Vasc Surg* 1997;26:517-38.
6. Al Shaqsi S, Lesche S, Thomson I. Cystic adventitial disease of the external iliac artery: a rare cause of claudication. *N Z Med J* 2015;128:61-4.
7. Gagnon J, Doyle DL. Adventitial cystic disease of common femoral artery. *Ann Vasc Surg* 2007;21:84-6.
8. Elster EA, Hewlett S, DeRienzo DP, Donovan S, Georgia J, Yavorski CC. Adventitial cystic disease of the axillary artery. *Ann Vasc Surg* 2002;16:134-7.
9. Paravastu SC, Regi JM, Turner DR, Gaines PA. A contemporary review of cystic adventitial disease. *Vasc Endovascular Surg* 2012;46:5-14.
10. Spinner RJ, Desy NM, Agarwal G, Pawlina W, Kalra M, Amrami K. Evidence to support that adventitial cysts, analogous to intraneural ganglion cysts, are also joint-connected. *Clin Anat* 2013;26:267-81.
11. Crolla RM, Steyling JF, Hennipman A, Slootweg PJ, Taams A. A case of cystic adventitial disease of the popliteal artery demonstrated by magnetic resonance imaging. *J Vasc Surg* 1993;18:1052-5.
12. Di Marzo L, Peetz DJ Jr, Bewtra C, Schultz RD, Feldhaus RJ, Anthonie G. Cystic adventitial degeneration of the femoral artery: is evacuation and cyst excision worthwhile as a definitive therapy? *Surgery* 1987;101:587-93.
13. Baxter AR, Garg K, Lamparello PJ, Mussa FF, Cayne NS, Berland T. Cystic adventitial disease of the popliteal artery: is there a consensus in management? *Vascular* 2011;19:163-6.
14. Apulian AK, Landry GJ. Basic data underlying decision making in nonatherosclerotic causes of intermittent claudication. *Ann Vasc Surg* 2015;29:138-53.
15. Van Rutte PW, Rouwet EV, Belgers EH, Lim RF, Teijink JA. In treatment of popliteal artery cystic adventitial disease, primary bypass graft not always first choice: two case reports and a review of the literature. *Eur J Vasc Endovasc Surg* 2011;42:347-54.
16. Do DD, Braunschweig M, Baumgartner I, Furrer M, Mahler F. Adventitial cystic disease of the popliteal artery: percutaneous US-guided aspiration. *Radiology* 1997;203:743-6.
17. Seo H, Fujii H, Aoyama T, Sasako Y. A case of adventitial cystic disease of the popliteal artery progressing rapidly after percutaneous ultrasound-guided aspiration. *Ann Vasc Dis* 2014;7:417-20.
18. Drac P, Kocher M, Utikal P, Cerna M, Kozak J, Bachleda P. Cystic adventitial disease of the popliteal artery: report on three cases and review of the literature. *Biomed Pap Med Fac Univ Palacky Olomouc Czech Repub* 2011;155:309-21.
19. Yurdakul M, Tola M. Resolution of adventitial cystic disease after unsuccessful attempt at aspiration. *J Vasc Interv Rad* 2011;22:412-4.

Submitted Jun 6, 2016; accepted Aug 12, 2016.